

台中榮民總醫院  
內部過敏免疫風濕科

系統性硬化症特別紀錄表

(1)

此處刷卡用

健保榮民	健保員工	健 保	健保員眷	民 眾	
姓名			病房	床位	年齡
					病歷號

Fulfillment of American Rheumatism Association Preliminary Criteria

for the Classification of Systemic Sclerosis\*

(Arthritis and Rheumatism 23 : 5 8 1-590'80)

**Major criteria :**

\_\_\_\_\_ Proximal scleroderma (tightness, thickening, and non-pitting induration, excluding the localized forms of scleroderma, proximal to the metacarpophalangeal or metatarsophalangeal joints, affecting other parts of the extremities, face , neck , or trunk (thorax or abdomen) ; usually bilateral, symmetrical and almost always including sclerodactyly)

**Minor criteria :**

- \_\_\_\_\_ 1. Sclerodactyly : limited to fingers and toes
- \_\_\_\_\_ 2. Digital pitting scars on fingertips or loss of substance of the distal finger pad (depressed areas at tips of digits or loss of digital pad tissue as a result of digital ischemia rather than trauma or exogenous causes)
- \_\_\_\_\_ 3. Bilateral basal pulmonary fibrosis(bilateral reticular pattern of linear or lineo nodular densities which are almost pronounced in basilar portions of the lungs on standard chest roentgenogram ; may assume appearance of diffuse mottling or “honeycomb lung”, and should not be primary lung disease

One major or two or more minor criteria were found in 97% of definite systemic sclerosis patients, but only in 2% of the comparison patients with systemic lupus erythematosus, polymyositis/dermatomyositis, or Raynaud’s phenomenon

\*Excludes localized scleroderma and pseudosclerodermatous disorders.

台中榮民總醫院  
內部過敏免疫風濕科

系統性硬化症特別紀錄表

(2)

此處刷卡用

健保榮民	健保員工	健 保	健保員眷	民 眾	
姓名			病房	床位	年齡
					病歷號

**Other clinical manifestations :**

- \_\_\_\_\_ 1. Bilateral finger or hand edema : firm but pitting edema, especially involving fingers (includes puffy, sausage-like swelling of fingers) or the dorsal aspect of the hands
- \_\_\_\_\_ 2. Abnormal skin pigmentation : hyperpigmentation often containing areas of punctuate or patchy hypopigmentation or depigmentation (“pepper and salt”)
- \_\_\_\_\_ 3. Telangiectasia : visible macular dilatation of superficial blood vessels which collapse upon pressure and fill slowly when pressure is released ; distinguished from rapidly filling spider angioma with central arteriole and from dilated linear superficial vessels
- \_\_\_\_\_ 4. Raynaud’s phenomenon : at least a two-phase color change in fingers and often toes consisting of pallor , cyanosis , and/or reactive hyperemia in response to cold exposure or emotion, as determined by patient’s history or physician’s observation
- \_\_\_\_\_ 5. Lower (distal) esophageal dysphagia: substernal discomfort on swallowing or sensation of food holdup in the retrosternal location
- \_\_\_\_\_ 6. Lower (distal) esophageal dysmotility : hypoperistalsis or aperistalsis, as demonstrated by either cine esophagogram or fluoroscopy or by manometric study, often accompanied by evidence of decrease in lower esophageal sphincter tone with reflux of gastric contents into the esophagus
- \_\_\_\_\_ 7. Colonic sacculations : wide-mouthed diverticula of colon located along the antimesenteric border, found on barium enema examination ; these sacculations may also occur in ileum and jejunum

台中榮民總醫院  
內部過敏免疫風濕科

系統性硬化症特別紀錄表

(3)

此處刷卡用

健保榮民	健保員工	健 保	健保員眷	民 眾			
姓名			病房	床位	年齡	病歷號	

Score for Scleroderma Skin Changes

Right					left					
0	1	2	3	4	Fingers	0	1	2	3	4
0	1	2	3	4	Hands	0	1	2	3	4
0	1	2	3	4	Forearms	0	1	2	3	4
0	1	2	3	4	Arms	0	1	2	3	4
0	1	2	3	4	Shoulders	0	1	2	3	4
					Neck	0	1	2	3	4
					Face	0	1	2	3	4
					Anterior Chest	0	1	2	3	4
0	1	2	3	4	Sreast	0	1	2	3	4
					Abdomen	0	1	2	3	4
					Upper Back	0	1	2	3	4
					Lower Back	0	1	2	3	4
0	1	2	3	4	Thighs	0	1	2	3	4
0	1	2	3	4	Legs	0	1	2	3	4
0	1	2	3	4	Feet	0	1	2	3	4
0	1	2	3	4	Toes	0	1	2	3	4

The degree of skin thickening is evaluated as following

- 0 = Normal
- 1 = Slight but definite thickening
- 2 = Mild-Moderate thickening
- 3 = Severe thickening
- 4 = Extreme degree of thickening

Maximal oral aperture ( interlabial aperture) \_\_\_\_\_cm

Finger- topalm distance \_\_\_\_\_cm

# 台中榮民總醫院 內部過敏免疫風濕科

系統性硬化症特別紀錄表

(4)

此處刷卡用

健保榮民	健保員工	健 保	健保員眷	民 眾	
姓名		病房	床位	年齡	病歷號

SCLEROSIS SINE  
SCLERODERMA

SCLEROACTYLY

ACROSCLEROSIS

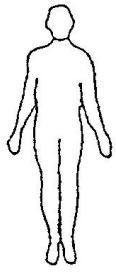
ACROSCLEROSIS

SSTICTO SENSU

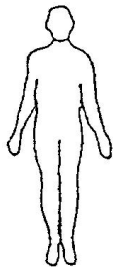
INTERMEDIATE

SYNOROME

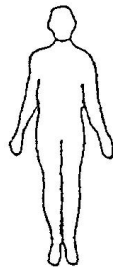ACUTE DIFFUSE  
SCLERODERMA



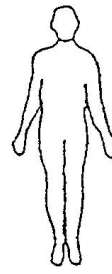1



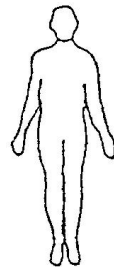2



3



4



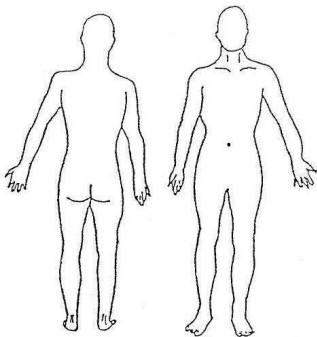
5

- uninvolved skin
- highly sclerotic skin
- moderately sclerotic skin
- possible but necessarily sclerotic skin

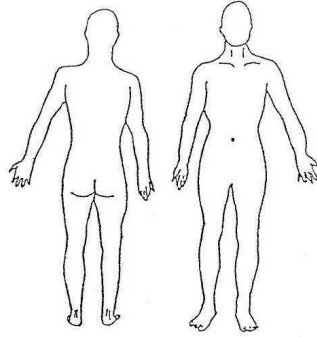
病人屬以上何種 TYPE 1) \_\_\_\_\_ 2) \_\_\_\_\_ 3) \_\_\_\_\_ 4) \_\_\_\_\_ 5) \_\_\_\_\_

並實際繪於下圖

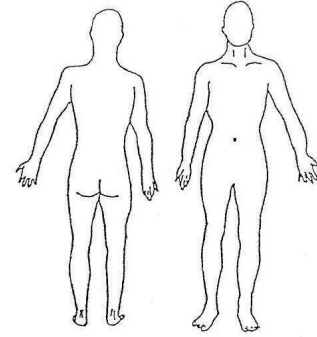
Date \_\_\_\_\_



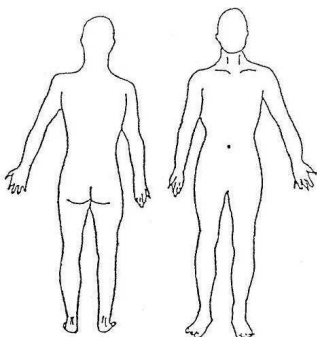
Date \_\_\_\_\_



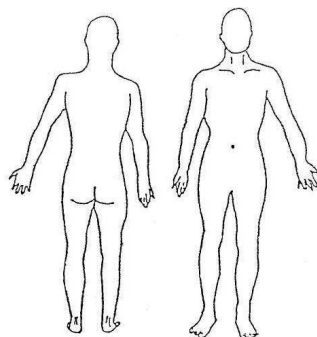
Date \_\_\_\_\_



Date \_\_\_\_\_



Date \_\_\_\_\_



Date \_\_\_\_\_

