出國報告（出國類別：出席國際會議）

第 34 屆亞太眼科醫學會出國報告

服務機關：台中榮民總醫院
姓名職稱：梁巧盈 醫師
派赴國家/地區：泰國
出國期間：108.3.5~108.3.9
報告日期：108.3.19

摘要

筆者於 108 年 3 月 5 日至 9 日赴泰國曼谷參加第 34 屆亞太眼科醫學會(APAO)。此醫學會與美國眼科醫學會 AAO、歐洲眼科醫學會 ESCRS、以及視覺科學研究醫學會(ARVO)並列世界四大眼科國際盛事。繼 106 年第 32 屆亞太眼科醫學會於台北舉辦後，本國眼科醫師更加踴躍參與此眼科盛會。會期共計四日，筆者積極參加了豐富的小児眼科及眼神經學研討會課程。此行收穫許多新知，其中對於精進臨床醫療最有助益的是有關於遺傳相關視神經及視網膜疾病的基因療法、以極低劑量 atropine 及 siRNA 眼藥水進行近視控制的最新進展、視神經炎的免疫標記分析(AQP4 & MOG 抗體)、微創斜視手術(radio-wave technique)、以及高危複視之鑑別診斷…等議題。此次會議中，筆者亦有發表兩篇小児眼科及眼神經學領域壁報論文，與各國學者專家交換心得。這趟 APAO 年會的密集學習，讓我忙碌的臨床工作中有效充電。也希望能將所見所聞最新的臨床發展運用在自己平日的醫療工作上，讓患者接受到更好的醫療照顧。

關鍵字: 亞太眼科醫學會，APAO

目　次

一、 目的

亞太眼科醫學會(Pancific-Asia Academy of Ophthalmology, 簡稱 APAO)，是亞洲及泛太平洋地區最盛大的眼科醫學會。與美國眼科醫學會 AAO、歐洲眼科醫學會 ESCRS、以及視覺科學研究醫學會(ARVO)並列世界四大眼科國際盛事。中華民國眼科醫學會在 APAO 會員組織中表現活躍且具高貢獻度。我國曾於 106 年順利主辦第 32 屆年會。今年 3 月 6 日至 3 月 9 日於泰國曼谷舉辦第 34 屆年會。為發表研究論文海報、持續吸收新知、提升專業學能與醫療服務品質，因此報名參加本次 APAO 年會。

二、 過程

本屆 APAO 在泰國曼谷 Queen Sirikit National Convention Center 舉辦。與會者超過 5000 人，論文報告 1500 篇，參展廠商 250 家，課程涵蓋眼科各次專科領域，規模盛大。筆者於 107 年 3 月 5 日抵達曼谷，當地氣溫約在攝氏 26~36 度之間，晴朗炎熱。會場位於曼谷市中心，臨近捷運站，搭乘大眾運輸系統相當快捷方便。大會貼心每日安排接駁車往返於飯店及會場之間，但因曼谷平面交通壅擠，若是搭乘大會接駁車常困在車陣中動彈不得，甚至上下班尖峰時段需要警車開道才得以前進。



大會課程非常豐富，涵蓋眼科各次專科領域課程。單就小兒眼科及眼神經學領域，每天都至少有 4~5 場次研討會可參加，可以盡情徜徉在海量知識裡。以下簡述一些對於精進臨床醫療最有助益的新知議題:

1. 遺傳相關視神經及視網膜疾病的基因療法: 繼適用於 retinitis pigmentosa 的基因療法眼內注射藥品通過美國 FDA 上市後，多種適用於 Lebers hereditary optic neuropathy 的基因療法藥物證在多國多中心人體試驗中，且已取得初步成效。唯此類藥品費用天價，動輒 1000~3000 萬台幣一劑。研發上市後恐怕病患難以負擔。

2. 近年使用極低劑量 Atropine 眼藥水控制近視逐漸成為主流。ATOM1&2 study 呈現 0.01% atropine 具有良好療效與較少的停藥後度數反彈。而近期其他 clinical trial (TNEC study) 顯示，0.05% atropine 與 0.01%、0.025%等較低濃度相較下，具有較佳療效，但停藥後反彈效應仍需長期追蹤。

3. 高危複視的鑑別診斷: 為幫助立即證確診斷高危險性的複視，會議中學者專家提出將原本的 P-ANIC sign 增加「急性發作」一項，成為 O-P-ANIC sign (onset, pain, pulsatile tinnitus, proptosis, papilledema, anisocoria, nystagmus, incomplete visual field, corneal hypoesthesia)。當病人呈現上述現象時需立即安排腦部影像檢查並密切追蹤，可能合併有 cavernous sinus disease, C-C fistula, aneurysm, orbital cellulitis, compressive lesions, posterior fossa disease, stroke, myasthenia gravis…等重症。

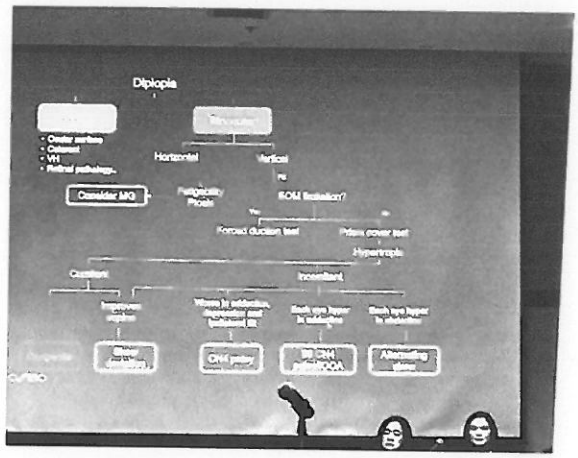

此次會議，筆者亦有發表兩篇小児眼科及眼神經學領域壁報論文，第一篇題目為「Remarkable recovery of visual function in a patient with genetic confirmed Leber's hereditary optic neuropathy. 基因變異確診的 Leber 氏遺傳性視神經病變視覺功能大幅進步的病例報告」 (e-Poster #200820)。第二篇題目為「Partial Oculomotor Nerve Palsy Caused by Neurosyphilis 神經性梅毒以部分動眼神經麻痺為表徵之病例報告」(e-Poster #200821)。在會場中與各國及我國的醫師舊雨新知互相交流，增長見聞，也收穫不少友誼。

APAO 年會的密集學習，讓我忙碌的臨床工作中有效充電。也希望能將所見所聞最新的臨床發展運用在自己平日的醫療工作上，讓患者接受到更好的醫療照顧。

三、 心得

1、 小兒眼科及眼神經學領域，臨床上最注重診斷技巧。此門疾病常無可見病灶且表現多元，為眼科的疑難雜症專科，「patient see nothing, doctor see nothing」即是此次專科醫師常有的診斷困境。每次醫學會時，總是十分珍惜與各大醫學中心醫師共同討論疑難病症的機會。此次 APAO 會議中，安排了許多場次的小兒眼科及眼神經學領域課程，並有兩場 chellange case 讓大家抽絲剝繭腦力激盪。內容精實，收穫豐富，內心充滿學習的喜樂。

2、 這次參加 APAO 年會，雖然註冊費不菲，但覺得值回票價、收穫很多。感謝醫院的補助，減輕不少負擔。

3、 此次是第一次造訪泰國。首都曼谷的繁榮進步、會議安排井然有序、工作人員專業友善。展現的國力以及人民素質，遠超我對東南亞國家的想像。衷心期盼我國能持續發展，增進國力，展現人民的自信心。

四、 建議

1、 建議給予明年度眼科同仁出席國際會議的預算。

2、 使用低濃度 atropine 眼藥水，是目前控制兒童近視的主流。目前臨床上已開始使用 0.01%、0.025%、0.05% 各種不同濃度 atropine，並已累積許多病例。日後宜持續加強近視防治衛教，累積臨床經驗，提升治療效果及滿意度。

五、 附錄 (大會節目簡表、參加證明、論文兩篇)

APAO Congress 2019 Program Overview



THE 34TH ASIA-PACIFIC ACADEMY OF OPHTHALMOLOGY CONGRESS

Certificate of Attendance

This serves to verify that

Chiao-ying LIANG

has attended

The 34th Asia-Pacific Academy of Ophthalmology (APAO) Congress
in conjunction with
The 43rd Annual Meeting of
the Royal College of Ophthalmologists of Thailand
Bangkok, Thailand
6-9 March 2019

Sincerely yours,

APAO 2019 BANGKOK — THE SCIENCES AND ARTS OF OPHTHALMOLOGY — 6-9 MARCH 2019, BANGKOK, THAILAND

REMARKABLE RECOVERY OF VISUAL FUNCTION IN A PATIENT WITH GENETIC CONFIRMED LEBER'S HEREDITARY OPTIC NEUROPATHY.

Chiao-Ying Liang.
Department of ophthalmology, Taichung Veterans General Hospital, Taiwan.

Introduction:

Leber hereditary optic neuropathy (LHON) is one of the most common inherited optic neuropathies causing bilateral central vision loss. The disorder results from point mutations in mitochondrial DNA and subsequent mitochondrial dysfunction. The primary cell type that is lost in LHON is the retinal ganglion cell, which is highly susceptible to disrupted ATP production and oxidative stress. Inheritance of LHON follows that of mitochondrial genetics, and it has a highly variable clinical phenotype, as other genetic and environmental factors also play a role. The prognosis of LHON is usually poor. Most LHON patients remain legally blind, but a small proportion can experience spontaneous partial recovery. We report a remarkable recovery of visual function in a patient with genetic confirmed (mtDNA14484 mutation) LHON.

Methods : A case report

Case report:

A healthy 14-year-old boy visited our clinic with the chief complain of bilateral painless subacute worsening of vision for 6 months. He had visited several eye clinic without definite diagnosis. He denied systemic disease and family history of major ocular disease. The previous tentative diagnosis included optic neuritis, keratotonus, amblyopia and psychosocial visual loss. OPD exam showed poor BCVA(0.05, OU), with nothing particular in the external eyes and clear eye media. The fundoscopy showed temporal pallor of bilateral optic discs.(Fig.1) Typical clinical signs of LHON such as dense cecocentral scotoma and gradually temporal sector optic atrophy were noted. Genetic test revealed mitochondrial DNA 14484 point mutation and confirmed the diagnosis of LHON. Supportive treatment with coenzyme Q10 and anti-oxidants was given. His vision stayed poor for several month. However in the 4th month of follow up period (10 months after disease attack), his visual acuity began to recover 6 months and gradually improved in the following 4 years. (Table 1) The latest follow up in Aug. 2015 at 18 year old showed BCVA 6/7.5 and Diminished cecocentral scotoma. (Fig.2) The patient is satisfied with the current visual status although the temporal sector optic atrophy remained unchanged. (Fig. 3)

Discussion:

LHON is resulted from point mutations in mitochondrial DNA and causes loss of RGC, the most common point mutation in Taiwan is 11778(92%). 14484(8%) and 3460(rare) were seldomly found in Taiwanese population. In our patient, a point mutation at 14484 locus was confirmed.

The prognosis of LHON is usually poor. Permanent vision loss and legally blind were the common scenario of the story. Occasionally, spontaneous visual improvement occur. The following are some known better prognostic factors: (1) 14484 point mutation (the recover rate of each point mutation are 14484(37-58%) > 3460(20%)>11778 (4%)), (2) heteroplasmy is bettern than homoplasmy, (3) some haplogroups are of better prognosis, such as haplogroup M8a, (4) young age, (5) a large optic disc. Our patient has point mutation 14484 and young age. Fortunately, he has the better chance of visual .

The treatment of mitochondrial disorders is still in its infancy. We are looking forward to several promising research underway. Ubiquinone analogs (idebenone, EPI-743) showed encouraging results in early stages of the disease. Current evidence of LHON-specific gene therapy also suggest promising treatment modalities. For now, a present effective and available treatment options for all LHON patients are still lacking

Conclusion:

The visual prognosis of LHON is usually poor, but partial vision recovery may happen in patients with m14484 mutation, heteroplasmy, young age, and large optic disc

APAO 2019 BANGKOK — THE SCIENCES AND ARTS OF OPHTHALMOLOGY — 6-9 MARCH 2019, BANGKOK, THAILAND

Partial Oculomotor Nerve Palsy Caused by Neurosyphilis

Chiao Ying Liang.
Department of ophthalmology, Taichung Veterans General Hospital, Taiwan.

Introductions

Neurosyphilis is a rare serious condition notable for its complex array of presentations, which is caused by the spirochete Treponema pallidum. Symptomatic neurosyphilis with isolated cranial nerves palsy as initial manifestation is rare. We report a case with neurosyphilis with initial presentation of weird oculomotor palsy and Argyll Robertson pupil.

Case report

The patient was a 25 year old heterosexual man without known sexual transmitted diseases (STD). He presented with acute onset of EOM limitation of left eye with diplopia for 4 months. On examination, his mental status was clear and cooperative. There were limitation of upgaze and medial gaze of the left eye, causing 18 PD exotropia and 9 PD left hypotropia. The intraocular findings were all negative except poliosis of eyelashes and bilateral pupillary paresis. The bilateral pupils were round but enlarged at 5 mm and nonreactive to direct and consensual light stimulation as well as near vision. Tracing back his history, he had been suffered from some weird multifocal neuromuscular symptoms for 4 years, including intermittent sharping pain of legs, dysuria, and hypersomnia. The presentation of cranial nerve palsy, pupillary paresis (Argyll -Robertson pupil) and multiple neuromuscular dysfunctions arouses the suspicion of neurosyphilis. Screening lab test for syphilis and other STD show strongly positive syphilis infection titer (RPR reactive 256 DIL, TPHA reactive >1:5120, FTA-ABS 3+, HIV neg). Lumbar puncture result (CSF VDRL 16X reactive) confirmed the diagnosis of neurosyphilis, but brain MRI showed negative finding. After antibiotics treatment of Ceftriaxone Inj 2gm IVA QD for 7 weeks, the follow up lumbar puncture show CSF VDRL 2X reactive. Although the Ceftriaxone treatment accomplished the treatment goal (syphilis titer decrease for more than 4-fold), all the symptoms/signs were persisted at 4-month follow up.

Figure 1. Poliosis of eyelashes, and bilateral pupil paresis (Argyll Robertson pupil)

Figure 2. Clinical presentation of oculomotor palsy, mixed with exotropia and hypotropia

Discussions

Traditionally, neurosyphilis is considered a form of late or tertiary syphilis, but CNS invasion by Treponema pallidumcan occur at any time after the initial infection and might actually occur more often than was previously thought, delayed recognition and treatment may result in irreversible sequelae.

Many patients with neurosyphilis are asymptomatic, but manifestations include subacute basal meningitis, a meningovascular syndrome of small deep cerebral infarction, cranial nerve palsy, chronic gummatous inflammation with focal intracranial mass lesions, chronic comportmental dementia of general paresis, and chronic sensory-ataxic myelopathy of tabes dorsalis. The early symptoms/signs of neurosyphilis were often nonspecific and complicated. Therefore, Such complex presentation or unexplained neurological symptoms in a patient should always raise the suspicion of neurosyphilis. All patients with suspected HIV infection or syphilis presenting with neurological symptoms should have brain MRI with contrast and undergo a lumber puncture with CSF analysis.

Conclusions

Neurosyphilis is uncommon, but still a significant disease with complex neurological presentation. It is highly recommended to screen for neurosyphilis in patients with cranial nerves palsy or other unexplained neurological findings. Early diagnosis and treatment of neurosyphilis is crucial due to potential persistent disabilities that can be easily treated or even prevented.